



Online article and related content  
current as of November 5, 2008.

## Does This Patient With Diabetes Have Osteomyelitis of the Lower Extremity?

Sonia Butalia; Valerie A. Palda; Robert J. Sargeant; et al.

*JAMA*. 2008;299(7):806-813 (doi:10.1001/jama.299.7.806)

<http://jama.ama-assn.org/cgi/content/full/299/7/806>

Correction	<a href="#">Contact me if this article is corrected.</a>
Citations	<a href="#">This article has been cited 1 time.</a> <a href="#">Contact me when this article is cited.</a>
Topic collections	Bacterial Infections; Infectious Diseases, Other; Radiologic Imaging; Diagnosis; Magnetic Resonance Imaging; Radiography; The Rational Clinical Examination; Endocrine Diseases; Diabetes Mellitus <a href="#">Contact me when new articles are published in these topic areas.</a>
CME course	<a href="#">Online CME course available.</a>
Related Articles published in the same issue	Osteomyelitis <a href="#">John L. Zeller et al. <i>JAMA</i>. 2008;299(7):858.</a>

Subscribe  
<http://jama.com/subscribe>

Permissions  
[permissions@ama-assn.org](mailto:permissions@ama-assn.org)  
<http://pubs.ama-assn.org/misc/permissions.dtl>

Email Alerts  
<http://jamaarchives.com/alerts>

Reprints/E-prints  
[reprints@ama-assn.org](mailto:reprints@ama-assn.org)

# Does This Patient With Diabetes Have Osteomyelitis of the Lower Extremity?

Sonia Butalia, MD

Valerie A. Palda, MD, MSc

Robert J. Sargeant, MD, MSc, PhD

Allan S. Detsky, MD, PhD

Ophyr Mourad, MD, MSc

## CLINICAL SCENARIOS

### Case 1

A 52-year-old woman is referred from the emergency department with a diabetic foot ulcer. She has type 1 diabetes mellitus that was first diagnosed at age 12 years. Her condition is complicated by nephropathy, retinopathy, and peripheral vascular disease. She has recently noticed erythema, swelling, and pain over the left foot. On physical examination, she has a pulse of 90/min, blood pressure of 136/84 mm Hg, and temperature of 36.1°C. Pedal pulses are diminished. There is a 2.2 × 1.5-cm ulcer in the toe webbing that probes to underlying bone. Investigations reveal a white blood cell count of 9500/μL and an erythrocyte sedimentation rate (ESR) of 75 mm/h. Wound swab Gram stain reveals gram-positive cocci and gram-negative bacilli. Radiographs of the foot identify soft tissue swelling and cortical erosion in the area of the ulcer. Should magnetic resonance imaging (MRI) of the foot be ordered?

### Case 2

A 64-year-old man is referred with a nonhealing ulcer. He has a small wound overlying the fourth metatar-

**Context** Osteomyelitis of the lower extremity is a commonly encountered problem in patients with diabetes and is an important cause of amputation and admission to the hospital. The diagnosis of lower limb osteomyelitis in patients with diabetes remains a challenge.

**Objective** To determine the accuracy of historical features, physical examination, and laboratory and basic radiographic testing. We searched for systematic reviews of magnetic resonance imaging (MRI) in the diagnosis of lower extremity osteomyelitis in patients with diabetes to compare its performance with the reference standard.

**Data Sources** MEDLINE search of English-language articles published between 1966 and March 2007 related to osteomyelitis in patients with diabetes. Additional articles were identified through a hand search of references from retrieved articles, previous reviews, and polling experts.

**Study Selection** Original studies were selected if they (1) described historical features, physical examination, laboratory investigations, or plain radiograph in the diagnosis of lower extremity osteomyelitis in patients with diabetes mellitus, (2) data could be extracted to construct 2 × 2 tables or had reported operating characteristics of the diagnostic measure, and (3) the diagnostic test was compared with a reference standard. Of 279 articles retrieved, 21 form the basis of this review. Data from a single high-quality meta-analysis were used to summarize the diagnostic characteristics of MRI in osteomyelitis.

**Data Extraction** Two authors independently assigned each study a quality grade using previously published criteria and abstracted operating characteristic data using a standardized instrument.

**Data Synthesis** The gold standard for diagnosis is bone biopsy. No studies were identified that addressed the utility of the history in the diagnosis of osteomyelitis. An ulcer area larger than 2 cm<sup>2</sup> (positive likelihood ratio [LR], 7.2; 95% confidence interval [CI], 1.1-49; negative LR, 0.48; 95% CI, 0.31-0.76) and a positive "probe-to-bone" test result (summary positive LR, 6.4; 95% CI, 3.6-11; negative LR, 0.39; 95% CI, 0.20-0.76) were the best clinical findings. A erythrocyte sedimentation rate of more than 70 mm/h increases the probability of a diagnosis of osteomyelitis (summary LR, 11; 95% CI, 1.6-79). An abnormal plain radiograph doubles the odds of osteomyelitis (summary LR, 2.3; 95% CI, 1.6-3.3). A positive MRI result increases the likelihood of osteomyelitis (summary LR, 3.8; 95% CI, 2.5-5.8). However, a normal MRI result makes osteomyelitis much less likely (summary LR, 0.14; 95% CI, 0.08-0.26). The overall accuracy (ie, the weighted average of the sensitivity and specificity) of the MRI is 89% (95% CI, 83.0%-94.5%).

**Conclusions** An ulcer area larger than 2 cm<sup>2</sup>, a positive probe-to-bone test result, an erythrocyte sedimentation rate of more than 70 mm/h, and an abnormal plain radiograph result are helpful in diagnosing the presence of lower extremity osteomyelitis in patients with diabetes. A negative MRI result makes the diagnosis much less likely when all of these findings are absent. No single historical feature or physical examination reliably excludes osteomyelitis. The diagnostic utility of a combination of findings is unknown.

*JAMA.* 2008;299(7):806-813

[www.jama.com](http://www.jama.com)

## See also Patient Page.

**CME available online at**  
 [www.jamaarchivescme.com](http://www.jamaarchivescme.com)  
 and questions on p 845.

**Author Affiliations:** Department of Medicine, St Michael's Hospital (Drs Butalia, Palda, Sargeant, and Mourad), Mt Sinai Hospital and University Health Network (Dr Detsky), Department of Health Policy Management and Evaluation, University of Toronto (Drs Palda and Detsky), Toronto, Ontario, Canada. Dr Butalia is now with the University of Calgary, Calgary, Alberta, Canada.

**Corresponding Author:** Ophyr Mourad, MD, MSc, St Michael's Hospital, 30 Bond St, Toronto, ON M5B 1W8, Canada ([mourado@smh.toronto.on.ca](mailto:mourado@smh.toronto.on.ca)).

**The Rational Clinical Examination Section Editors:** David L. Simel, MD, MHS, Durham Veterans Affairs Medical Center and Duke University Medical Center, Durham, NC; Drummond Rennie, MD, Deputy Editor.

sal head of his right foot that was first noted 3 weeks ago. He was prescribed a 10-day course of antibiotics and referred to a podiatrist for further foot care. This man has a history of type 2 diabetes complicated by neuropathy, nephropathy, and retinopathy. He has no prior history of neuropathic diabetic foot ulcer. On examination, the wound is round, measuring 1 cm in diameter, with associated erythema and swelling. It does not probe to bone. Laboratory investigations reveal a white blood cell count of 14 500/ $\mu$ L, an ESR of 25 mm/h, and a hemoglobin A<sub>1c</sub> of 8.2%. Foot radiographs reveal no abnormalities. Gram stain and culture of the wound swab identify gram-positive cocci and gram-negative bacilli. How likely is osteomyelitis?

### WHY IS THIS DIAGNOSIS IMPORTANT?

Foot-related complications account for up to 20% of all diabetes-related admissions in the North American diabetic population.<sup>1</sup> Medicare data from 1995 to 1996 revealed that US \$1.45 billion was spent directly on diabetic foot ulcer care in the United States alone.<sup>2</sup> Diabetic foot problems are the most common cause of nontraumatic amputations,<sup>3</sup> with infection responsible for a large proportion of these cases.<sup>4</sup> When inadequately treated, osteomyelitis increases the risk of amputation.<sup>5</sup> The perioperative 30-day mortality of patients having lower extremity amputation is reported to be 7.4%.<sup>6</sup>

The diagnosis of lower limb osteomyelitis in patients with diabetes remains a challenge. The classic signs and symptoms of infection may be absent or masked by the coexistence of vascular disease and neuropathy. The gold standard for the diagnosis of osteomyelitis is a bone biopsy and culture. This invasive procedure is not always practical<sup>7</sup> and may be contraindicated in patients with diabetes and severe peripheral vascular disease. It is therefore important to determine the features of the history, physical examination, and prelimi-

nary investigations that aid in the diagnosis of osteomyelitis to minimize costly and invasive investigations and initiate appropriate and timely therapy. Herein, we summarize the test characteristics of the history, physical examination, routinely available laboratory measurements and radiographs, and MRI for evaluating lower extremity osteomyelitis in patients with diabetes.

## CLINICAL EVALUATION OF THE LOWER EXTREMITY IN PATIENTS WITH DIABETES

### History

The evaluation for osteomyelitis and other infections begins with an assessment of a patient's diabetes and the risk factors that predispose a patient to skin breakdown. The history taking should include duration of diabetes, glycemic control, microvascular or macrovascular disease, and presence of peripheral neuropathy and peripheral vascular disease. In addition, the clinician should inquire about recent trauma and history of ulcers.

### Physical Examination

On physical examination, the clinician should assess for local and systemic features of infection such as fever, chills, hypotension, and presence and appearance of wound or ulcer (erythema, swelling, purulence, size, and depth).<sup>7-10</sup> The clinician should note the presence of foot deformities, tenderness, neuropathy, and venous or arterial insufficiency.<sup>11,12</sup> Because of neuropathy, patients may not perceive foreign bodies within the ulcer.

It is sometimes difficult to distinguish between lower extremity ulcers due to diabetes and those caused primarily by venous or arterial insufficiency. Venous ulcers are typically found above the medial or lateral malleoli and frequently have irregular borders. Arterial ulcers often affect the toes or the shins, with the borders of the ulcer being pale and appearing as if they have been punched out. These ulcers may lack granulation tissue and are typically painful in the absence of co-

### Box 1. Wagner Grading Scale

Grade 0: no open lesions; may have evidence of healed lesions or deformities

Grade 1: superficial ulcer

Grade 2: deeper ulcer to tendon, bone, or joint capsule

Grade 3: deeper tissues involved, with abscess, osteomyelitis, or tenosynovitis

Grade 4: localized gangrene of toe or forefoot

Grade 5: gangrene of foot (partial or total)

existing neuropathy. Diabetic ulcers usually occur at areas of increased pressure, such as the sole of the foot, or areas where shoes have rubbed against the skin.<sup>13</sup> Although any ulcer is a risk factor for osteomyelitis, the traumatized skin in a patient with vascular insufficiency is also prone to this disease process.<sup>14</sup>

**Ulcer Area.** One method for quantifying ulcer size is to multiply the longest and widest diameters of the lesion.<sup>9</sup> This may not be a completely accurate estimation of ulcer area, as some ulcers may be round or irregularly shaped.

**Probe-to-Bone Test.** The probe-to-bone test of a foot ulcer is performed at the bedside with a sterile, blunt, stainless steel probe. The examiner gently probes the wound for the presence of a rock-hard, gritty structure at the wound base in the absence of any intervening soft tissue. The presence of such a finding indicates a positive probe-to-bone result, whereas the inability to probe the base of a wound to periosteum or bone is a negative result.<sup>10</sup>

**Wagner Grade.** Wagner<sup>8</sup> developed a scale to grade foot ulcers based on observations. Foot ulcers are graded from 0 to 5 based on depth of lesion and presence or absence of features of infection and/or gangrene (BOX 1). A limitation of the Wagner grading scale is

**Box 2. Criteria for Level of Evidence in Diagnostic Studies**

Level I: independent, blind comparison of test (ie, sign, symptom, or investigation) results with a gold standard of anatomy, physiology, diagnosis, or prognosis among a large number of consecutive patients ( $\geq 30^a$ ) with suspected target condition

Level II: independent, blind comparison of test results with gold standard among a small number of consecutive patients with suspected target condition

Level III: independent, blind comparison of test results with a gold standard among nonconsecutive patients with suspected target condition

Level IV: nonindependent comparison of test results with a gold standard among a “grab” sample of patients who obviously have the target condition (and perhaps healthy individuals)

Level V: nonindependent comparisons of test results with a standard of uncertain validity (which may incorporate the test results in its definition) among “grab” samples of patients (and perhaps healthy individuals)

<sup>a</sup>When a finding occurs in 0 of 30 patients, the upper confidence limit for 0% is 10%. A study with 0 of 20 patients having the finding would have an upper confidence limit of 14%.

that all deep tissue infections (including abscess, tendinitis, and osteomyelitis) are accounted for in a single grade.

**METHODS****Search Strategy and Study Selection**

We searched the MEDLINE electronic database for English-language articles between 1966 and March 2007 using the following search terms: *osteomyelitis*, *diabet\$*, *signs and symptoms*, *physical examination*, *diagnosis*, *diagnostic tests*, and “*sensitivity and specificity*.” We identified additional references by modifying a previously published search strategy.<sup>15</sup> This strategy combined 9 exploded Medical Subject Headings (*physical examination*, *medical history taking*, *professional competence*, “*sensitivity and specificity*,” *reproducibility of results*, *observer variation*, “*diagnostic tests*, *routine*,” *decision support techniques*, and *Bayes theorem*). We then took the intersection of this set with osteomyelitis and diabetes mellitus (exploded). We identified additional articles through a hand search of references from retrieved articles, previous reviews, and polling experts. The titles and abstracts (when available) of the articles retrieved were evaluated

to determine their eligibility for our review. Publications in abstract and letter form were included to minimize publication bias.

Articles were included for review if they fulfilled all of the following criteria: (1) they were original studies describing historical features, physical examination, laboratory investigations, or plain radiograph in the diagnosis of lower extremity osteomyelitis in patients with diabetes mellitus, (2) data could be extracted to construct  $2 \times 2$  tables or the article reported operating characteristics of the diagnostic measure, and (3) the diagnostic test was compared with a reference standard. Studies in pediatric populations or mixed populations of patients with and without diabetes were excluded. Data from a single high-quality meta-analysis, not conforming to the prespecified search criteria and data extraction, were used to summarize the test characteristics of MRI in patients with diabetes who were thought to have osteomyelitis.

**Reference Standard**

Bone biopsy is the gold standard for the diagnosis of osteomyelitis. Ideally, bone specimens should have both microbiological and histological analysis; however, we required the

gold standard for osteomyelitis to be culture or histological results because patients had often received antibiotic therapy before bone biopsy or surgical intervention, thus lowering the yield of bone culture.

**Quality Review**

One author (S.B.) identified potential articles by screening the retrieved articles and by searching through the bibliographies of these articles. Two authors independently reviewed articles for quality and extracted the operating characteristics of the diagnostic tests. Each article was rated using a topic-specific quality rating scale that used published principles<sup>16</sup> as well as a modified quality checklist specific to the Rational Clinical Examination series<sup>17</sup> (BOX 2).

**Data Analysis**

Likelihood ratios (LRs) predicting the presence of osteomyelitis, given a positive test result (sensitivity/ $1 - \text{specificity}$ ) and a negative test result ( $1 - \text{sensitivity}/\text{specificity}$ ) were calculated for each outcome of interest using published raw data.<sup>18</sup> Where 2 or more studies examined the same clinical variable, we calculated summary LR and 95% confidence intervals (CIs) using the DerSimonian and Laird random-effects approach.<sup>19</sup> Estimated variances of LR were computed using the usual methods for ratios of proportions,<sup>20</sup> with their reciprocals used as study weights. In studies with a zero cell count, the value 0.5 was added to each cell count to permit use of this variance estimation. All analyses were performed using R software, version 2.01.<sup>21</sup>

**RESULTS****Study Characteristics**

The electronic literature search identified 279 studies, of which 21 met our inclusion criteria and form the basis of our review (TABLE 1 and FIGURE).<sup>9,10,22-40</sup> The included studies accounted for a total of 1027 patients. Three studies reported sensitivity or specificity but not both.<sup>23,32,36</sup> Eight studies prospectively

evaluated patients.<sup>9,10,22-24,30-32</sup> One meta-analysis of the test performance of MRI for the diagnosis of osteomyelitis of the

foot and ankle included 11 studies in patients with diabetes and accounted for a total of 275 patients.<sup>41</sup>

**Prior Probability of Osteomyelitis**

The prevalence of osteomyelitis in the selected studies ranged from 12%

**Table 1.** Studies Addressing Diagnosis of Lower Extremity Osteomyelitis in Patients With Diabetes Mellitus

Source	Level of Evidence	Study Type	Population	Prevalence of Osteomyelitis, %	Biopsy, %	Methods of Reaching a Final Diagnosis
Newman et al, 1991 <sup>9</sup>	II	Prospective	Inpatients and outpatients with foot ulcer (n = 35)	68 <sup>a</sup>	100 <sup>a</sup>	Histology and/or culture
Grayson et al, 1995 <sup>10</sup>	III	Prospective	Inpatients with severe limb-threatening foot infections (n = 75)	66 <sup>a</sup>	61 <sup>a</sup>	Histology or radiological evidence of bone destruction in association with an infected ulcer and/or purulent, friable, nonviable bone
Wang et al, 1990 <sup>22</sup>	III	Prospective	Inpatients with suspected osteomyelitis (n = 32)	74 <sup>b</sup>	100 <sup>b</sup>	Histology
Johnson et al, 1996 <sup>23</sup>	III	Prospective	Suspected osteomyelitis (n = 22)	NA	72	Culture and histology or clinical follow-up
Enderle et al, 1999 <sup>24</sup>	III	Prospective	Suspected osteomyelitis and indication for minor amputation (n = 19)	74	100	Histology
Lee et al, 1986 <sup>25</sup>	III	Retrospective	Cellulitis or foot ulcers (n = 90)	27	Not stated	Surgical and pathologic "proof" or a positive bone scan with clinical response to therapy
Shone et al, 2006 <sup>26</sup>	III	Retrospective	Outpatients (n = 81)	20 <sup>a</sup>	Not stated	Clinical in association with radiological evidence and, when necessary, MRI or deep tissue samples
Park et al, 1982 <sup>27</sup>	III	Retrospective	Variety of ischemic infections and/or ischemic problems (n = 39)	67	100	Histology
Weinstein et al, 1993 <sup>28</sup>	III	Retrospective	Inpatients with suspected osteomyelitis, nonhealing ulcer, or soft tissue infection (n = 32)	74 <sup>b</sup>	100 <sup>b</sup>	Histology
Yuh et al, 1989 <sup>29</sup>	III	Retrospective	Suspected osteomyelitis and/or nonhealing foot ulcers (n = 14)	86 <sup>b</sup>	100 <sup>b</sup>	Histology
Lavery et al, 2007 <sup>30</sup>	IV	Prospective	Outpatients (n = 247)	12	NA	Culture
Shults et al, 1989 <sup>31</sup>	IV	Prospective	Foot ulcers or infection limited to forefoot (n = 32)	72	100	Culture
Croll et al, 1996 <sup>32</sup>	IV	Prospective	Inpatients with foot infections (n = 27)	33	78	Histology, bone culture, or response to medical management
Keenan et al, 1989 <sup>33</sup>	IV	Retrospective	Suspected osteomyelitis (n = 77)	44 <sup>b</sup>	47 <sup>c</sup>	Culture and/or histology or clinical evidence
Larcos et al, 1991 <sup>34</sup>	IV	Retrospective	Suspected osteomyelitis (n = 51)	27	55	Bone biopsy or culture or deep-wound culture during debridement or clinical follow-up as outpatient
Seldin et al, 1985 <sup>35</sup>	IV	Retrospective	Suspected osteomyelitis (n = 30)	60 <sup>d</sup>	60	Histology and/or culture or clinical resolution of symptoms without prolonged antibiotic therapy
Kaleta et al, 2001 <sup>36</sup>	IV	Retrospective	Inpatients (n = 29)	66	53	Histology, positive results of at least 2 imaging modes (bone scan, MRI, radiograph), or positive probe to bone
Levine et al, 1994 <sup>37</sup>	IV	Retrospective	Suspected osteomyelitis complicating a soft tissue infection ((n = 27)	45 <sup>c</sup>	62 <sup>c</sup>	Histology, surgical observation of lack of communication between infected region and bone, or clinical resolution
Oyen et al, 1992 <sup>38</sup>	IV	Retrospective	Suspected osteomyelitis (n = 16)	44	56	Histology or clinically
Armstrong et al, 1996 <sup>39</sup>	V	Retrospective	Inpatients (n = 28)	100	100	Intraoperative bone cultures at time of admission and/or histological evidence of osteomyelitis
Vesco et al, 1999 <sup>40</sup>	V	Retrospective	Inpatients (n = 24)	54	0	Clinical bone involvement (ie, the ability to probe to bone), radiologic evidence of bone involvement, positive combined radionuclide imaging and MRI, or clinical evidence of bone involvement during follow-up

Abbreviations: MRI, magnetic resonance imaging; NA, could not be determined with data provided.

<sup>a</sup>Calculations based on number of ulcers.

<sup>b</sup>Calculations based on number of bone specimens.

<sup>c</sup>Calculations based on number of cases.

<sup>d</sup>Calculations based on number of radiographs.

to 100%. A retrospective cohort study of 8905 patients with diabetes found that 15% of those with a foot ulcer developed osteomyelitis at or after diagnosis.<sup>42</sup> The prior probability that a leg ulcer in a patient with diabetes will end up being osteomyelitis is more likely to reflect this

value than the values found in the highly selected group of patients in the included studies.

**Precision of Symptoms, Signs, and Investigations for Osteomyelitis**

There were no studies identified that addressed the precision of symptoms,

signs, or investigations in the diagnosis of lower extremity osteomyelitis.

**Accuracy of Symptoms and Signs for Osteomyelitis**

No studies were identified that addressed the utility of any component of the history in the diagnosis of osteomyelitis.

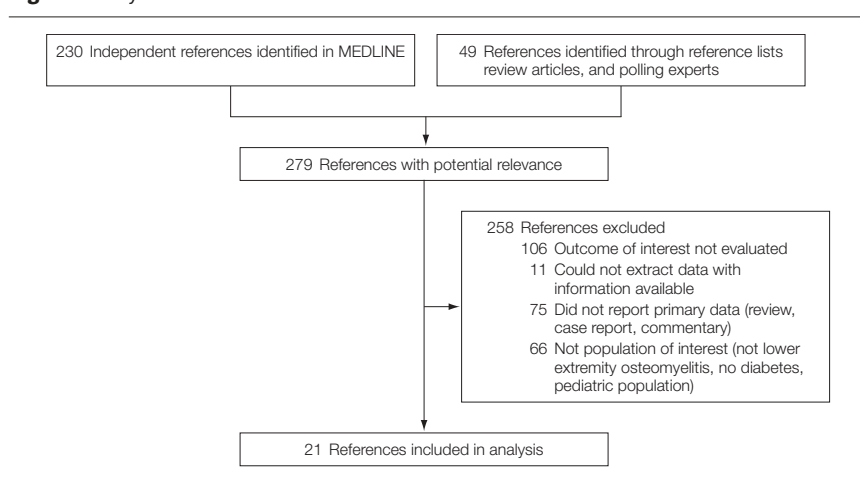
Seven studies assessed physical examination findings in the diagnosis of lower extremity osteomyelitis.<sup>9,10,24,26,30,39,40</sup> The 7 studies included a total of 509 patients. No studies examined the test characteristics of a combination of findings. Temperature was examined in a single study, which received a level V quality rating (nonindependent comparisons of test results with a standard of uncertain validity) and demonstrated a poor sensitivity of 19%; patients without osteomyelitis were not included, so specificity and LRs could not be calculated.<sup>39</sup>

“Bone exposure” as a single finding suggests osteomyelitis (LR, 9.2; 95% CI, 0.57-146; TABLE 2). While the absence of bone exposure, defined as visualization of bone either directly or after probing, has a much narrower CI and lowers the likelihood of osteomyelitis, the LR of 0.70 (95% CI, 0.53-0.92) is not low enough to rule out osteomyelitis unless the pretest probability is already very low.

Good-quality evidence<sup>9</sup> suggests that an ulcer area larger than 2 cm<sup>2</sup> (calculated as described above) makes osteomyelitis more likely (LR, 7.2; 95% CI, 1.1-49), while an ulcer area smaller than 2 cm<sup>2</sup> decreases the likelihood of osteomyelitis by about half (LR, 0.48; 95% CI, 0.31-0.76). The presence or absence of ulcer inflammation (erythema, swelling, purulence) does not modify the probability of disease (positive LR, 1.5; 95% CI, 0.51-4.7; negative LR, 0.84; 95% CI, 0.56-1.3).<sup>9</sup>

The probe-to-bone test has been evaluated in 3 studies.<sup>10,26,30</sup> Shone et al<sup>26</sup> and Lavery et al<sup>30</sup> studied the probe-to-bone test in an outpatient setting, while Grayson et al<sup>10</sup> prospectively evaluated the probe-to-bone test in 75

**Figure. Study Selection**



**Table 2. Diagnostic Accuracy of Physical Examination and Laboratory Investigations for Lower Extremity Osteomyelitis in Patients With Diabetes Mellitus**

Source	Examination Maneuver/Finding	Positive LR (95% CI)	Negative LR (95% CI)
<b>Signs</b>			
Lavery et al, 2007 <sup>30</sup>	Positive probe-to-bone finding <sup>a</sup>	9.4 (6.1-15)	0.15 (0.06-0.37)
Grayson et al, 1995 <sup>10</sup>	Positive probe-to-bone finding <sup>a</sup>	4.3 (1.7-10)	0.40 (0.26-0.61)
Shone et al, 2006 <sup>26</sup>	Positive probe-to-bone finding <sup>a</sup>	4.5 (1.8-11)	0.68 (0.48-0.95)
	Summary LR	6.4 (3.6-11)	0.39 (0.20-0.76)
Newman et al, 1991 <sup>9</sup>	Bone exposure <sup>a</sup>	9.2 (0.57-146)	0.70 (0.53-0.92)
Newman et al, 1991 <sup>9</sup>	Ulcer area >2 cm <sup>2a</sup>	7.2 (1.1-49)	0.48 (0.31-0.76)
Newman et al, 1991 <sup>9</sup>	Ulcer inflammation (erythema, swelling, purulence) <sup>a</sup>	1.5 (0.51-4.7)	0.84 (0.56-1.3)
<b>Clinical Gestalt</b>			
Newman et al, 1991 <sup>9</sup>	Clinical judgment <sup>a</sup>	9.2 (0.57-147)	0.70 (0.53-0.92)
Vesco et al, 1999 <sup>40</sup>	Wagner grade >2 <sup>a</sup>	13 (0.82-203)	0.48 (0.27-0.86)
Enderle et al, 1999 <sup>24</sup>	Wagner grade >2 <sup>a</sup>	3.9 (0.96-16)	0.04 (0-0.70)
	Summary LR <sup>b</sup>	5.5 (1.8-17)	0.54 (0.30-0.97)
<b>Laboratory Findings</b>			
Kaleta et al, 2001 <sup>36</sup>	ESR ≥70 mm/h	19 (1.3-290)	0.13 (0.04-0.42)
Newman et al, 1991 <sup>9</sup>	ESR >70 mm/h <sup>a</sup>	6.4 (0.39-105)	0.74 (0.54-1.0)
	Summary LR <sup>c</sup>	11 (1.6-79)	0.34 (0.06-1.9)
Oyen et al, 1992 <sup>38</sup>	Swab culture <sup>d</sup>	1 (0.65-1.5)	1 (0.08-13)

Abbreviations: CI, confidence interval; ESR, erythrocyte sedimentation rate; LR, likelihood ratio.

<sup>a</sup>Calculations based on number of ulcers.

<sup>b</sup>Summary LR of clinical judgment and Wagner grade.

<sup>c</sup>Armstrong et al<sup>39</sup> studied ESR but we did not include that study's data in the summary LR because patients without osteomyelitis were not included, so specificity and LRs could not be calculated.

<sup>d</sup>Calculations based on number of swab cultures.

patients with suspected severe limb-threatening infection. A positive probe-to-bone test result increases the likelihood of osteomyelitis (summary LR, 6.4; 95% CI, 3.6-11). A negative probe-to-bone test result has a summary LR of 0.39 (95% CI, 0.20-0.76).

Three studies described the diagnostic accuracy of clinical gestalt.<sup>9,24,40</sup> One study described the diagnostic accuracy of "clinical judgment"<sup>9</sup> and 2 studies used the Wagner grading scale.<sup>24,40</sup> Because the Wagner grade is a subjective assessment, we elected to summarize the data together with clinical judgment. The clinical impression of osteomyelitis, without formal rules or weighting of the findings, increases the likelihood of osteomyelitis about 5-fold (summary LR, 5.5; 95% CI, 1.8-17). When a clinician judges that osteomyelitis is absent, the likelihood decreases (summary LR, 0.54; 95% CI, 0.30-0.97) (Table 2). These data suggest that clinicians might be more proficient at detecting the presence of osteomyelitis than detecting its absence.

### Accuracy of Laboratory Investigations for Osteomyelitis

Four studies evaluated the utility of laboratory investigations in the diagnosis of osteomyelitis<sup>9,36,38,39</sup> (Table 2). The 4 studies included a total of 108 patients, a rather small number. Three studies of varying quality evaluated the utility of ESR.<sup>9,36,39</sup> The cutoff used to define an elevated ESR varied among the studies. An ESR of more than 70 mm/h increases the probability of the diagnosis of osteomyelitis with a summary positive LR of 11 (95% CI, 1.6-79.0), while an ESR of less than 70 mm/h has a summary LR of 0.34 (95% CI, 0.06-1.90)<sup>9,36</sup> (Table 2) with a 95% CI that crosses 1.0.

The value of an elevated white blood cell count was examined in a single study and demonstrated poor sensitivity (range, 14%-54%) regardless of the cutoff studied.<sup>39</sup> Patients without osteomyelitis were not included in this study, so specificity and LRs could not be calculated.<sup>39</sup>

**Table 3.** Diagnostic Accuracy of Plain Radiographs for Lower Extremity Osteomyelitis in Patients with Diabetes Mellitus<sup>a</sup>

Source	Definition Used to Interpret Radiographs	Positive LR (95% CI)	Negative LR (95% CI)
Newman et al, 1991 <sup>9</sup>	Cortical erosion in the area of the foot ulcer <sup>b</sup>	3.4 (0.46-24)	0.79 (0.58-1.1)
Yuh et al, 1989 <sup>29</sup>	Permeated radiolucencies, destructive changes, and/or periosteal new bone formation <sup>c</sup>	3.0 (0.54-17)	0.33 (0.14-0.82)
Weinstein et al, 1993 <sup>28</sup>	Permeative radiolucencies, destructive changes, cortical defects, and periosteal reaction <sup>c</sup>	2.8 (0.97-8.0)	0.59 (0.40-0.86)
Oyen et al, 1992 <sup>38</sup>	Soft tissue swelling, osteoporosis, osteolysis, and cortical or medullary destruction and sequestration <sup>d</sup>	2.7 (0.92-8.0)	0.54 (0.22-1.3)
Larcos et al, 1991 <sup>34</sup>	Bone destruction alone or in combination with soft tissue swelling, osteopenia, or periosteal reaction; localized osteopenia or periosteal reaction in the absence of fracture or neuropathic joint disease <sup>d</sup>	2.5 (0.97-6.4)	0.69 (0.43-1.1)
Park et al, 1982 <sup>27</sup>	Cortical defects associated with soft tissue swelling or subcutaneous gas	2.0 (0.84-4.8)	0.56 (0.30-1.0)
Seldin et al, 1985 <sup>35</sup>	Focal cortical and/or medullary destruction or destruction of opposing joint space surfaces <sup>d</sup>	1.9 (0.99-3.5)	0.13 (0.02-0.98)
Summary LR		2.3 (1.56-3.3)	0.63 (0.51-0.78)

Abbreviations: CI, confidence interval; LR, likelihood ratio.

<sup>a</sup>Only studies that clearly defined what constitutes an abnormal radiograph are included.

<sup>b</sup>Calculations based on number of ulcers.

<sup>c</sup>Calculations based on number of bone specimens.

<sup>d</sup>Calculations based on number of radiographs.

Swab culture<sup>38</sup> was examined in a single study and had no diagnostic utility, with positive and negative LRs of 1.0 (95% CI for positive LR, 0.65-1.5; 95% CI for negative LR, 0.08-13) (Table 2), suggesting that in patients with suspected osteomyelitis, a positive swab was equally common in patients with and without biopsy-proven osteomyelitis.

### Accuracy of Plain Radiographs for Osteomyelitis

Sixteen studies that included 567 patients assessed the accuracy of plain radiographs in the diagnosis of lower extremity osteomyelitis.\* The studies included a broad range of patients and plain radiographs were often studied concurrently with another radiologic technique (magnification radiography, ultrasound, bone scan, or MRI). Only 6 of the 16 studies were prospec-

tive.<sup>9,22-24,31,32</sup> Some studies used 3 views<sup>9,28,35</sup> and others used 2 views,<sup>24,31</sup> but for the most part it was unclear how many views were taken.†

The characteristic signs of osteomyelitis on plain radiograph include focal loss of trabecular pattern, periosteal reaction, and frank bone destruction, often accompanied by soft tissue swelling.<sup>43</sup> The studies that clearly stated a definition for a positive radiographic result incorporated 1 or more of these features and were used to calculate summary LRs (TABLE 3).

Radiographic results alone appear to be marginally useful if positive, with a summary LR of 2.3 (95% CI, 1.6-3.3), and less useful when negative for osteomyelitis (summary LR, 0.63; 95% CI, 0.51-0.78) (Table 3). We found no studies that address the utility of serial radiographs in the diagnosis of osteomyelitis.

\*References 9, 22-25, 27-29, 31-35, 37, 38, 40.

†References 22, 23, 25, 27, 29, 32-35, 37, 38, 40.

### Other Clinical Considerations

**Soft Tissue Culture.** We identified 3 studies<sup>44-46</sup> that compared superficial swab culture with bone culture. Swab culture identified the identical pathogens as bone culture in only 19% to 36% of isolates. Superficial swab cultures do not reliably predict bone microorganisms.

**Other Radiological Modes Including MRI.** A comprehensive review of all radiological modes in the evaluation and diagnosis of lower extremity osteomyelitis is beyond the scope of this review. The utility of nuclear scans and MRI in the diagnosis of osteomyelitis have been recently reviewed elsewhere.<sup>41,47</sup> A recent meta-analysis reported that nuclear imaging (technetium, indium, and white blood cell scans) lacks specificity (62%-88.5%) in the diagnosis of osteomyelitis.<sup>47</sup> Kapoor et al<sup>41</sup> recently summarized the test characteristics of MRI in foot osteomyelitis. Eleven of the 16 MRI studies included exclusively patients with diabetes. Magnetic resonance imaging was shown to have a sensitivity of 90% (range, 77%-100%) and a specificity of 83% (range, 40%-100%) in all patients and a summary positive LR of 3.8 (95% CI, 2.5-5.8) and a summary negative LR of 0.14 (95% CI, 0.08-0.26) in patients with diabetes.<sup>41</sup> Magnetic resonance imaging was also shown to be more accurate than technetium Tc 99m bone scan, plain radiography, and white blood cell scan. The overall accuracy (ie, the weighted average of the sensitivity and specificity) of MRI is 89% (95% CI, 83.0-94.5).

### Limitations of the Literature

There are several important limitations to consider when interpreting the presented studies. We identified only 10 studies that attained a level II or III quality rating, with the remainder considered to be of overall poor quality. The majority of studies evaluated were of retrospective design and had unblinded protocols. Aside from study design, the physical examination findings and maneuvers were often described in a single study<sup>9,38,39</sup> and the

precision was not addressed.<sup>9,10,24,26,40</sup> The accuracy of combinations of variables is unknown.

Patients were studied most often in tertiary care centers, thus resulting in a selection bias. For example, 1 study that evaluated the probe-to-bone test was in patients with severe limb-threatening infection.<sup>10</sup>

The study by Newman et al<sup>9</sup> that discussed the diagnostic accuracy of clinical impression did not clearly define what this entailed, thus limiting reproducibility.

In the studies that addressed the utility of plain radiographs, details of the definition used to interpret the radiograph were missing in more than half of the studies.<sup>22-25,31-33,37,40</sup> Also not defined was the time between clinical presentation and the time the radiograph was performed. Bony changes associated with osteomyelitis may take 7 to 15 days after the onset of the infectious process before they are identified on plain radiographs.<sup>29</sup>

Patients who lacked features commonly suggestive of osteomyelitis were less likely to have a bone biopsy. This form of bias, referred to as verification bias, occurs when the decision to perform the gold standard test (bone biopsy or culture) is influenced by the results of clinical variables or screening test being studied. This will in turn inappropriately increase the apparent sensitivity of the test and decrease its apparent specificity.

### SCENARIO RESOLUTION

#### Case 1

While there is some uncertainty about the pretest probability of osteomyelitis in a patient with diabetes and a lower extremity ulcer, our best estimate is 15%. Using each clinical predictor individually, an ulcer area of larger than 2 cm<sup>2</sup> with an LR of 7.2 (95% CI, 1.1-49) increases the likelihood of osteomyelitis to 56%, and the positive finding of probing to bone (LR, 6.4; 95% CI, 3.6-11) increases the probability of osteomyelitis to 53%. The elevation in ESR with a positive LR of 11 (95% CI, 1.6-79) increases the probability of os-

teomyelitis from 15% to 66%. While most clinicians believe that the presence of these 3 variables together would make the diagnosis of osteomyelitis certain, the literature does not speak to the accuracy of combinations of variables (as noted in the aforementioned limitations). At this point, most clinicians would treat as osteomyelitis. Those who are uncomfortable with the uncertainties in these data might choose to order an MRI. A positive MRI result in combination with any one of these clinical variables increases the probability of osteomyelitis to greater than 80% (assuming independence of the LRs).

#### Case 2

The physical examination features and laboratory and radiographic results are not helpful in this case presentation to make a diagnosis of osteomyelitis. As indicated herein, ulcer area larger than 2 cm<sup>2</sup>, a positive probe to bone, an ESR greater than 70 mm/h, or an abnormal radiographic finding are more likely to be associated with osteomyelitis, but none of the testing modes in our review, with the exception of MRI, displayed clinically useful negative LRs for ruling out osteomyelitis. Assuming a prevalence of 15%, a negative MRI finding decreases the probability of osteomyelitis to 2.4%, thus effectively excluding the diagnosis. The elevated white blood cell counts and positive wound swab cultures are not diagnostically helpful.

### CLINICAL BOTTOM LINE

Osteomyelitis of the foot causes significant morbidity in patients with diabetes, with a significant financial burden to patients and the institutions caring for these patients. Although there is no substitute for a detailed history, its utility in the diagnosis of osteomyelitis in patients with diabetes has not been well studied. The available evidence suggests that an ulcer that measures more than 2 cm<sup>2</sup> or a positive probe-to-bone finding may be helpful to establish the diagnosis. An ESR greater than 70 mm/h or positive plain radiograph findings appear to be help-

ful in increasing the likelihood of osteomyelitis. Magnetic resonance imaging results should be interpreted in the context of the pretest probability. Temperature, ulcer inflammation, white blood cell count, and swab culture do not appear to be helpful in establishing the diagnosis or directing therapy in patients with diabetes and a lower extremity ulcer.

**Author Contributions:** Dr Butalia had full access to all of the data in the study and takes responsibility for the integrity of the data and the accuracy of the data analysis.

**Study concept and design:** Butalia, Palda, Sargeant, Detsky, Mourad.

**Acquisition of data:** Butalia, Palda, Sargeant, Mourad. **Analysis and interpretation of data:** Butalia, Palda, Sargeant, Detsky, Mourad.

**Drafting of the manuscript:** Butalia, Palda, Sargeant, Mourad.

**Critical revision of the manuscript for important intellectual content:** Butalia, Palda, Sargeant, Detsky, Mourad.

**Administrative, technical, or material support:** Butalia. **Study supervision:** Palda, Sargeant, Detsky, Mourad.

**Financial Disclosures:** None reported.

**Additional Contributions:** Ben Powers, MD, and Tally Lassiter, MD, Duke University and Durham VA Medical Center, reviewed the manuscript and provided clinical input and George Tommlinson, BSc, MSc, PhD, University of Toronto, assisted with statistical calculations. No compensation was received for these contributions.

## REFERENCES

- Canadian Diabetes Association Clinical Practice Guidelines Expert Committee. Canadian Diabetes Association 2003 clinical practice guidelines for the prevention and management of diabetes in Canada. *Can J Diabetes*. 2003;27(suppl 2):S1-S152. <http://www.diabetes.ca/cpg2003/downloads/cpgcomplete.pdf>. Accessed January 15, 2008.
- Harrington C, Zagari MJ, Corea J, Klitenic J. A cost analysis of diabetic lower-extremity ulcers. *Diabetes Care*. 2000;23(9):1333-1338.
- Green MF, Aliabadi Z, Green BT. Diabetic foot: evaluation and management. *South Med J*. 2002;95(1):95-101.
- Pecoraro RE, Reiber GE, Burgess EM. Pathways to diabetic limb amputation: basis for prevention. *Diabetes Care*. 1990;13(5):513-521.
- Bamberger DM, Daus GP, Gerding GN. Osteomyelitis in the feet of diabetic patients: long-term results, prognostic factors, and the role of antimicrobial and surgical therapy. *Am J Med*. 1987;83(4):653-660.
- Subramaniam B, Pomposelli F, Talmor D, Park KW. Peri-operative and long term morbidity and mortality after above knee and below knee amputations in diabetics and nondiabetics. *Anesth Analg*. 2005;100(5):1241-1247.
- Williams DT, Hilton JR, Harding KJ. Diagnosing foot infection in diabetes. *Clin Infect Dis*. 2004;39(suppl 2):S83-S86.
- Wagner FW Jr. The dysvascular foot: a system for diagnosis and treatment. *Foot Ankle*. 1981;2(2):64-122.
- Newman LG, Waller J, Palestro CJ, et al. Unsuspected osteomyelitis in diabetic foot ulcers: diagnosis and monitoring by leukocyte scanning with indium in 111 oxoquinoline. *JAMA*. 1991;266(9):1246-1251.
- Grayson ML, Gibbons GW, Balogh K, Levin E, Karchmer AW. Probing to bone in infected pedal ulcers: a clinical sign of underlying osteomyelitis in diabetic patients. *JAMA*. 1995;273(9):721-723.
- Hill SL, Holtzman GI, Buse R. The effects of peripheral vascular disease with osteomyelitis in the diabetic foot. *Am J Surg*. 1999;177(4):282-286.
- Khan NA, Rahim SA, Anand SS, Simel DL, Panju A. Does the clinical examination predict lower extremity peripheral arterial disease? *JAMA*. 2006;295(5):536-546.
- London NJM, Donnelly R. ABC of arterial and venous disease: ulcerated lower limb. *BMJ*. 2000;320(7249):1589-1591.
- Lew DP, Waldvogel FA. Osteomyelitis. *N Engl J Med*. 1997;336(14):999-1007.
- Lederle FA, Simel DL. Does this patient have abdominal aortic aneurysm? *JAMA*. 1999;281(1):77-82.
- Jaeschke R, Guyatt G, Sackett DL; Evidence-Based Medicine Working Group. Users' guides to the medical literature, III: how to use an article about a diagnostic test, A: are the results of the study valid? *JAMA*. 1994;271(5):389-391.
- Steiner MJ, DeWalt DA, Byerley JS. Is this child dehydrated? *JAMA*. 2004;291(22):2746-2754.
- Sackett DL. A primer on the precision and accuracy of the clinical examination. *JAMA*. 1992;267(19):2638-2644.
- DerSimonian R, Laird N. Meta-analysis in clinical trials. *Control Clin Trials*. 1986;7(3):177-188.
- Rosner B. *Fundamentals of Biostatistics*. Belmont, CA: Duxbury Press; 1995.
- R Development Core Team. *R: A Language and Environment for Statistical Computing*. Vienna, Austria: R Foundation for Statistical Computing; 2004.
- Wang A, Weinstein D, Greenfield L, et al. MRI and diabetic foot infections. *Magn Reson Imaging*. 1990;8(6):805-809.
- Johnson JE, Kennedy EJ, Shereff MJ, Patel NC, Collier BD. Prospective study of bone, indium-111-labeled white blood cell, and gallium-67 scanning for the evaluation of osteomyelitis in the diabetic foot. *Foot Ankle Int*. 1996;17(1):10-16.
- Enderle MD, Coerper S, Schweizer HP, et al. Correlation of imaging techniques to histopathology in patients with diabetic foot syndrome and clinical suspicion of chronic osteomyelitis: the role of high-resolution ultrasound. *Diabetes Care*. 1999;22(2):294-299.
- Lee SM, Lee RG, Wilinsky J, Balogh K, Clouse ME. Magnification radiography in osteomyelitis. *Skeletal Radiol*. 1986;15(8):625-627.
- Shone A, Burnside J, Chipchase S, Game F, Jeffcoate W. Probing the validity of the probe-to-bone test in the diagnosis of osteomyelitis of the foot in diabetes. *Diabetes Care*. 2006;29(4):945.
- Park HM, Wheat LJ, Siddiqui AR, et al. Scintigraphic evaluation of diabetic osteomyelitis. *J Nucl Med*. 1982;23(7):569-573.
- Weinstein D, Wang A, Chambers R, Stewart CA, Motz HA. Evaluation of magnetic resonance imaging in the diagnosis of osteomyelitis in diabetic foot infections. *Foot Ankle*. 1993;14(1):18-22.
- Yuh WT, Corson JD, Baraniewski HM, et al. Osteomyelitis of the foot in the diabetic patients: evaluation with plain film, 99m-Tc-MDP bone scintigraphy, and MR imaging. *AJR Am J Roentgenol*. 1989;152(4):795-800.
- Lavery LA, Armstrong DG, Peters EJG, Lipsky BA. Probe-to-bone test for diagnosing diabetic foot osteomyelitis: reliable or relic? *Diabetes Care*. 2007;30(2):270-274.
- Shults DW, Hunter GC, McIntyre KE, Parent FN, Piotrowski JJ, Bernhard VM. Value of radiographs and bone scans in determining the need for therapy in diabetic patients with foot ulcers. *Am J Surg*. 1989;158(6):525-529.
- Croll SD, Nicholas GG, Osborne MA, Wasser TE, Jones S. Role of magnetic resonance imaging in the diagnosis of osteomyelitis in diabetic foot infections. *J Vasc Surg*. 1996;24(2):266-270.
- Keenan AM, Tindel NL, Alavi A. Diagnosis of pedal osteomyelitis in diabetic patients using current scintigraphic techniques. *Arch Intern Med*. 1989;149(10):2262-2266.
- Larcos G, Brown ML, Sutton RT. Diagnosis of osteomyelitis of the foot in diabetic patients: value of 111-In-leukocyte scintigraphy. *AJR Am J Roentgenol*. 1991;157(3):527-531.
- Seldin DW, Heiken JP, Feldman F, Alderson PO. Effect of soft-tissue pathology on detection of pedal osteomyelitis in diabetics. *J Nucl Med*. 1985;26(9):988-993.
- Kaleta JL, Flieschli JW, Reilly CH. The diagnosis of osteomyelitis in diabetes using erythrocyte sedimentation rate. *J Am Podiatr Med Assoc*. 2001;91(9):445-450.
- Levine SE, Neagle CE, Esterhai JL, Wright DG, Dalinka MK. Magnetic resonance imaging for the diagnosis of osteomyelitis in the diabetic patient with a foot ulcer. *Foot Ankle Int*. 1994;15(3):151-156.
- Oyen WJ, Netten PM, Lemmens JA, et al. Evaluation of infectious diabetic foot complications with indium-111-labeled human nonspecific immunoglobulin G. *J Nucl Med*. 1992;33(7):1330-1336.
- Armstrong DG, Lavery LA, Sariaya M, Ashry H. Leukocytosis is a poor indicator of acute osteomyelitis of the foot in diabetes mellitus. *J Foot Ankle Surg*. 1996;35(4):280-283.
- Vesco L, Boulahouir H, Hamissa S, et al. The value of combined radionuclide and magnetic resonance imaging in the diagnosis and conservative management of minimal or localized osteomyelitis of the foot in diabetic patients. *Metabolism*. 1999;48(7):922-927.
- Kapoor A, Page S, LaValley M, Gale D, Felson DT. Magnetic resonance imaging for diagnosing foot osteomyelitis: a meta-analysis. *Arch Intern Med*. 2007;167(2):125-132.
- Ramsey SD, Newton K, Blough D, et al. Incidence, outcomes, and cost of foot ulcers in patients with diabetes. *Diabetes Care*. 1999;22(3):382-387.
- Mettler MA. *Essentials of Radiology*. 2nd ed. Philadelphia, PA: Elsevier Saunders; 2005.
- Senneville E, Melliez H, Beltrand E, et al. Culture of percutaneous bone biopsy specimens for diagnosis of diabetic foot osteomyelitis: concordance with ulcer swab cultures. *Clin Infect Dis*. 2006;42(1):57-62.
- Kessler L, Piemont Y, Ortega F, et al. Comparison of microbiological results of needle puncture vs superficial swab in infected diabetic foot ulcer with osteomyelitis. *Diabet Med*. 2006;23(1):99-102.
- Lavery LA, Sariaya M, Ashry H, Harkless LB. Microbiology of osteomyelitis in diabetic foot infections. *J Foot Ankle Surg*. 1995;34(1):61-64.
- Capriotti G, Chianelli M, Signore A. Nuclear medicine imaging of diabetic foot infection: results of meta-analysis. *Nucl Med Commun*. 2006;27(10):757-764.